

Details

Your reference:	anonymous
Our reference:	123010
Requested for:	anonymous
Requested by:	anonymous
Date job requested:	20 Sep 2014
Date job completed:	22 Sep 2014
Joint side:	Right

Summary

Simulated motion was limited.
Femoral version is larger than normal (35.2°).
Femoral inclination is larger than normal (138.0°).
Anterior acetabular coverage is lower than normal.
The LCE angle is smaller than normal (20.4°).
Acetabular version is higher than normal (28.1°).
Alpha angles are normal.

Disclaimer

This report was computed using analysis software and represents a simplified model of clinical reality. While we took great care in its production, it may happen that your clinical findings deviate from aspects of this report. For this reason we ask you to please take note of the disclaimer on Page [5](#).

This is the interactive 3D view



1. Viewing the 3D analysis requires Adobe Reader 9.0 or newer.
You can download Adobe Reader from <http://get.adobe.com/reader>



2. Apple computers are shipped with a viewer that is not suitable for this report.
Please install Adobe Reader for Mac OS.



3. For further support please visit www.clinicalgraphics.com/support.aspx

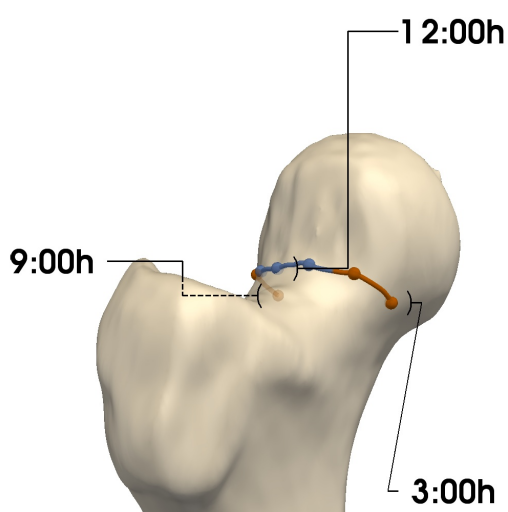
Click here to activate the 3D view,
then use the mouse to interact

Femur

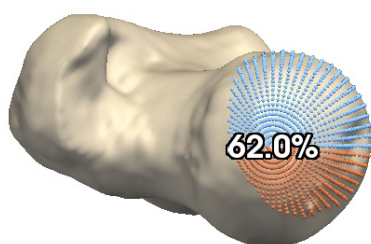
Head diameter: 42.3 mm
Neck diameter: 31.7 mm Normal:
Neck version: 35.2° (0.4%-19.0%)
Neck inclination: 138.0° (123.0%-135.4%)*

*(Toogood et al., 2009)

Alpha angles



Acetabular coverage



Posterior coverage:	38.8%	Normal (35%-43%)
Anterior coverage:	23.2%	(30%-38%)
Total coverage:	62.0%	(66%-81%)*

*(Dandachli et al., 2008)

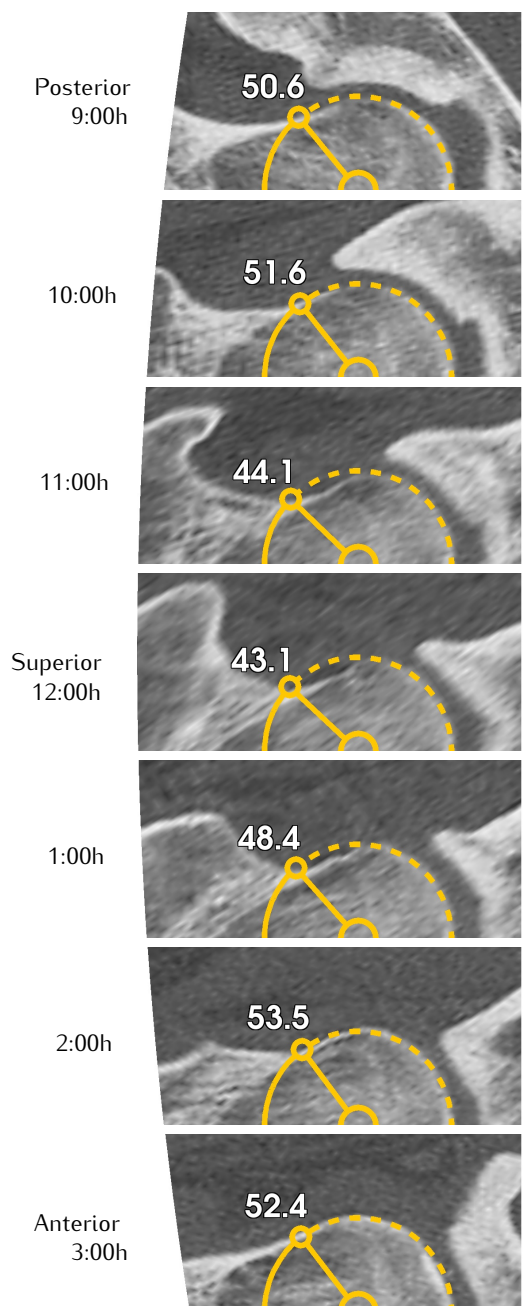
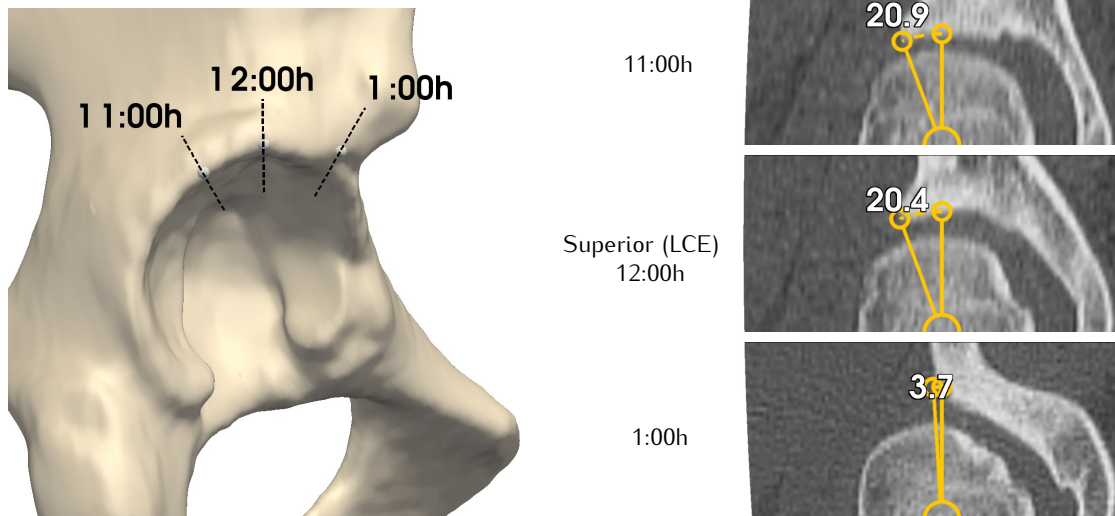


Figure 1: Clockwise alpha angles.

Acetabulum

Acetabular cup diameter: 48.1 mm

Center edge angle



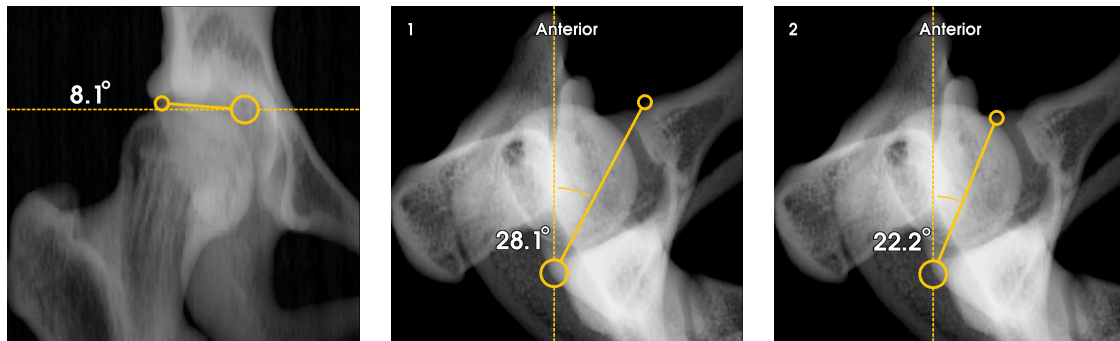
Expected range for LCE between 22° and 33° ([Tannast et al., 2011](#))

Acetabulum orientation

Sourcil Angle: 8.1°

Version: 28.1°
Normal: 16° - 26°
([Köhnlein et al., 2009](#))

Version of upper hemisphere*: 22.2°



* The version measurement in the right-most image is calculated halfway between the joint center and the roof of the acetabulum, corresponding to line number 2 in the left-most image.

Disclaimer

This analysis report was generated by Clinical Graphics B.V. using custom-made analysis software. This report is not intended as a replacement for established methods used for the diagnosis and evaluation of pathologies and/or injury. Clinical Graphics B.V. does not accept responsibility for treatment decisions or treatment outcome. In no event shall Clinical Graphics be liable for direct or indirect damages resulting from use of this report. Medical and health care providers should exercise their own independent clinical judgement. Patients should always consult with health care providers and inform them on the terms and conditions as set forth on the Clinical Graphics B.V. website at www.clinicalgraphics.com. No suggested or implied test or procedure should be carried out unless the patient's health care provider deems it justified, independent of the contents of this report.

References

- Dandachli, W., Kannan, V., Richards, R., Shah, Z., Hall-Craggs, M., Witt, J., 2008. Analysis of cover of the femoral head in normal and dysplastic hips: New CT-based technique. *J Bone Joint Surg Br* 90-B, 1428–1434.
- Köhnlein, W., Ganz, R., Impellizzeri, F., Leunig, M., 2009. Acetabular Morphology: Implications for Joint-preserving Surgery. *Clinical orthopaedics and related research* 467 (3), 682–691.
- Tannast, M., Albers, C., Steppacher, S., Siebenrock, K., 2011. Hip pain in the young adult. In: *EFORT European Instructional Lectures*. pp. 141–154.
- Toogood, P., Skalak, A., Cooperman, D., 2009. Proximal femoral anatomy in the normal human population. *Clinical orthopaedics and related research* 467 (4), 876–885.

Acknowledgements

We wish to acknowledge the research contributions of Dr. R.M. Bloem (Reinier de Graaf Groep, Delft, The Netherlands), Dr. T. Hogervorst (Haga Ziekenhuis, Den Haag, The Netherlands), Drs. S.P.L. Jansen (Rijnland Ziekenhuis, Leiderdorp, The Netherlands) and Mr. J. Witt (UCL/The London Clinic, London, United Kingdom).

Have questions?

We will be happy to answer any questions you may have! Our phone lines are open during working hours (time zone GMT +1) at +31 15 744 0137. You may also contact us by e-mail: support@clinicalgraphics.com.